

Langerhans cell histiocytosis oral lesions in pediatric patients

Verónica H Pavan^{id}, Virginia Fernández de Preliasco^{id}, Melisa Ienco^{id},
Carolina Benchuya^{id}

Universidad de Buenos Aires, Facultad de Odontología, Cátedra Odontología Integral Niños, Ciudad Autónoma de Buenos Aires, Argentina.

ABSTRACT

Langerhans cell histiocytosis (LCH) is a disease with unknown etiology. It presents as single-system (affecting a single organ or tissue) or as multisystem (with or without risk organ involvement). The oral cavity may be involved or be the site of the first manifestation. **Aim:** To describe, group, and determine the frequency of oral lesions in pediatric patients with LCH, and to relate these lesions to age and the different disease subtypes. **Materials and Method:** Clinical and radiographic examinations were used to evaluate 95 patients diagnosed with LCH, aged 0 to 16 years, who were referred to the Department of Comprehensive Pediatric Dentistry at the School of Dentistry, University of Buenos Aires. Clinical histories were prepared and informed consents obtained. Lesions were diagnosed by observation, palpation and biopsies, and grouped according to affected tissues into bone, mucosal, and bone-mucosal. **Results:** 42.1% presented oral lesions, and in 14.73%, these lesions were the first manifestation of LCH. Ninety percent presented only bone lesions, while the remaining 10% presented bone-mucosal and mucosal lesions. In the single-system subtype, 52.5% presented bone lesions. In the multisystem subtypes (with or without risk organs), all three types of lesions were found. The association between age at which LCH was diagnosed and oral tissue involvement showed that bone-mucosal lesions occur in young children (average age 1.4 years) diagnosed with multisystem LCH. Oral mucosa was only affected in reactivations of the disease. **Conclusions:** A high frequency of oral lesions was observed, which were sometimes the first manifestation of the disease, most often affecting bone tissue. Dentists can play an active role in the initial diagnosis of the disease.

Keywords: Histiocytosis, Langerhans Cell - oral lesions, children

Lesiones bucales de Histiocitosis de Células de Langerhans en pacientes pediátricos

RESUMEN

La Histiocitosis de células de Langerhans (LCH) (Langerhans cell histiocytosis) es una enfermedad de etiología aún desconocida. Se presenta en forma unisistémica (afecta un solo órgano o tejido) o multisistémica (con o sin órganos de riesgo afectados). La cavidad bucal puede estar comprometida o ser el sitio de la primera manifestación. **Objetivo:** describir, agrupar y determinar la frecuencia de las lesiones bucales de pacientes pediátricos con LCH, relacionarlas con la edad y los diferentes subtipos de la enfermedad. **Materiales y Método:** se evaluaron mediante exámenes clínicos y radiográficos 95 pacientes entre 0 y 16 años con diagnóstico de LCH, derivados a la Cátedra de Odontología Integral Niños, Facultad de Odontología, Universidad de Buenos Aires. Se confeccionaron historias clínicas y se obtuvieron los consentimientos informados. Las lesiones fueron diagnosticadas a través de observación, palpación y biopsias, y se agruparon según los tejidos afectados en óseo, mucoso y óseo-mucoso. **Resultados:** el 42.1% presentó lesiones bucales y en el 14.73% estas fueron la primera manifestación de LCH. El 90% mostró solo lesiones óseas, mientras que en el 10 % restante se observaron lesiones óseo-mucosas y mucosas. En el subtipo unisistémico el 52.5% presentó lesiones óseas. En los subtipos multisistémicos, "con" o "sin" órganos de riesgo, se hallaron los tres tipos de lesiones. La relación entre la edad de diagnóstico de LCH y el compromiso de tejidos bucales evidenció que las lesiones óseo-mucosas ocurren en niños pequeños (edad promedio 1.4 años) con diagnóstico de LCH multisistémica. La mucosa bucal solo se vio afectada en las reactivaciones de la enfermedad. **Conclusiones:** Se observó una alta frecuencia de lesiones bucales, siendo en ocasiones la primera manifestación de la enfermedad, afectando con mayor frecuencia al tejido óseo. El odontólogo puede desempeñar un rol activo en el diagnóstico inicial de la enfermedad.

Palabras clave: Histiocitosis de células de Langerhans - lesiones bucales, niños

To cite:

Pavan VH, Fernández de Preliasco V, Ienco M, Benchuya C. Langerhans cell histiocytosis oral lesions in pediatric patients. Acta Odontol Latinoam. 2023 Dec 31;36(3):156-162. <https://doi.org/10.54589/aol.36/3/156>

Corresponding Author:

Verónica H Pavan
veronica.pavan@odontologia.uba.ar

Received: August 2023.
Accepted: October 2023.



This work is licensed under a Creative Commons Attribution-NonCommercial 4.0 International License

INTRODUCTION

Langerhans-cell histiocytosis (LCH) is an infrequent disease. Its pathogenesis is unknown but may be a dysregulation of the immune response as a result of inappropriate stimulation of the immune system or a myeloid neoplasm. It has been associated to a mutation of the gene BRAF 600 E and activation of ERK¹⁻³. In 50 % to 90 % of the cases diagnosed, patients are between less than one year old to 15 years old⁴, with an estimated annual incidence of 2 to 10 cases per million children⁵.

LCH is characterized by the abnormal accumulation and proliferation of histiocytes, eosinophiles and pathological Langerhans cells, and may involve one or multiple tissues and systems. The cell infiltrate destroys the affected tissues⁶.

In contrast to usual skin cells, pathological Langerhans cells appear round, functionally and immunologically immature, surrounded by eosinophiles, macrophages, lymphocytes, and sometimes giant multinucleate cells⁵. Diagnosis is performed by biopsy of the lesion to ascertain presence of Birbeck granules, and immunohistochemical confirmation by the markers CD1a, S100 or CD207. CD1a is specific to and distinctive of Langerhans cells⁷.

Clinical manifestations include asymptomatic lesions, single lesions that remit, or multisystem disorders⁸. Bone lesions have been reported in 82% of patients with LCH. Lesions were generally associated to painful swelling, which could be the most frequent initial sign. The bones in which LCH was most frequently found were skull (27%), mandible and maxilla (11%), and the long bones femur (13%), humerus (5%) and tibia (3%)⁹. In the oral cavity, there may be lytic bone lesions in one or several areas, pathological mandibular fractures, pain, sores, periodontal involvement with marked tooth mobility, early tooth eruption, or mobility and premature loss of primary or permanent teeth¹⁰⁻¹².

According to the organs involved, the disease is grouped into three subtypes:

- Single-system (SS LCH): a single organ or tissue is involved.
- Multisystem with risk organs involved (MS LCH RO⁺): Risk organs include liver, bone marrow, and any involved in the central nervous system such as skull and face bones (orbit, malar or maxillary bone). These lesions may extend to the soft intracranial tissue and

are often associated with diabetes insipidus.

- Multisystem without risk organs involved (MS LCH RO⁻): Lesions are located on skin, bone or lymph nodes¹³.

New LCH lesions at the same site as was previously affected or at a different site from the original one is called reactivations. Their seriousness may be the same as or different from the initial lesion, and they may occur in the oral cavity^{14,15}.

There is no report in the literature on the grouping of lesions, association with age, or LCH subtypes. The aims of this study are therefore to group lesions according to the tissue involved (bone, bone-mucosa and mucosa), determine the frequency of oral lesions in pediatric patients with LCH, and relate them to age and the different subtypes of the disease.

MATERIALS AND METHOD

This study evaluated 95 patients with confirmed LCH diagnosis who were referred from different hospitals to the Department of Comprehensive Pediatric Dentistry at the School of Dentistry at Buenos Aires University (FOUBA).

Inclusion criteria were newborn to 16-year-old children with LCH diagnosis confirmed by pathohistological study, by presence of Birbeck granules and positive immunological markers CD1a and S100 or CD207 in cells from the lesion. Exclusion criterion was patients with non-Langerhans histiocytosis.

The following information was recorded in each patient's clinical history: personal data, medical and family background, including date of diagnosis and status of the disease (activity or remission). Informed consent was obtained and the procedures to be followed were explained to patients. This study was approved by the FOUBA Ethics Committee (CETICA N°006/2019), in keeping with the principles in the Declaration of Helsinki.

Diagnosis and location of oral lesions: Each patient underwent extraoral and intraoral clinical diagnosis. Panoramic radiographs were taken to detect any osteolytic lesions of the jaws and the degree of dental involvement in patients whose age and cooperation so allowed. Periodical radiographs were taken in cases where radiolucency or tooth mobility was observed. Axial or volumetric CT

scans were requested to ascertain lesion size and extension towards surrounding tissues.

Oral lesions were grouped according to affected tissue as follows: 1) *bone lesions*; 2) *mucosal lesions*, and 3) *bone-mucosal lesions*.

When oral lesions were present, biopsies were taken and the tissue sent to the Surgical Pathology Laboratory at the Department of Pathological Anatomy, FOUBA.

Statistical analysis

This was a retrospective, observational, cross-sectional study. Descriptive statistics were calculated, CI 95%, chi-square test and Kruskal Wallis test to compare LCH type groups, different types of oral lesions and ages.

RESULTS

The sample consisted of 95 patients, 56.84% male, average age at time of consultation with dentist 5.4 ± 3.7 years, average age at diagnosis of the disease 2.7 ± 2.9 years, while average ages at diagnosis for the different subtypes SS LCH, MS-RO⁺ LCH and MS-RO⁻ LCH were 4.06, 0.6 and 1.42 years, respectively; ($p < 0.001$). Table 1 shows the distribution of patients according to disease subtypes and whether oral lesions were present. In the group with oral lesions, 35.0 % had SS LCH, 7.5 % had MS-RO⁺ LCH, and 57.5 % had MS-RO⁻ LCH ($p < 0.001$).

Oral lesions were present in 42.1% of the patients:

- 1) Bone lesions: Closed osteolytic lesions within mandibular or maxillary bone that do not involve the oral mucosa. These lesions may produce facial swelling or pain (Figs. 1A and B).
- 2) Mucosal lesions: Pericoronitis in first permanent molars. During permanent tooth eruption there may be inflammation and pain in the marginal gum (Fig. 1C) with presence of a surrounding reddish halo. Pericoronitis persists until the tooth is fully erupted.
 - 2.a) Palatal mucosal lesion: Rash-like, flat erythematous lesion on palatal mucosa (Fig. 1D).
 - 2.b) Labial mucosal lesion: Lesion on labial mucosa with persistent, erosive or ulcerous loss of substance (Fig. 1E).

Table 1. Distribution of patients according to LCH subtype and presence of oral lesions

LCH Subtype	Patients with LCH (n=95)					
	Without oral lesions (n = 55)			With oral lesions (n = 40)		
	57.8% CI 47.3 – 67.9			42.2% CI 32.0- 52.7		
	N	%	CI 95%	N	%	CI 95%
SS LCH	30	54.5	40.7 - 67.8	14	35	20.5 – 51.7
MS-RO ⁺ LCH	3	5.5	1.4 - 16.1	3	7,5	1.5 – 20.4
MS-RO ⁻ LCH	22	40	27.3 - 54.1	23	57.5	40.8-72.9

- 3) Bone-mucosal lesions: Extensive lesions involving both jaws and compromising alveolar processes. Teeth lacking bone support present severe mobility, pain, pathological root resorption and/or exposed cement. These conditions may lead to spontaneous tooth loss. The osteolytic alveolar bone lesion may induce primary or permanent tooth eruption earlier than the normal sequence, without adequate crown calcification or with little root formation. Radiographs show radiolucent areas surrounding affected teeth (Figs. 1F and 1G).

Table 2 shows that, regarding lesions, 52.5 % were in bone tissue, 40 % in bone-mucosal tissues, and 7.5 % involved only mucosal tissues ($p = 0.002$).

Table 3 shows children's average age at the time of LCH diagnosis according to the oral tissue involved ($p=0.212$).

Bone and bone-mucosal lesions were found in lower jaw, followed by upper jaw. Mucosa of the palate, lip and jugal zone were less frequently affected.

Oral lesion was the first LCH manifestation detected in 14.73% of patients. Table 4 shows the oral tissues involved. The most frequent was bone tissue, with 85.8 % ($p= 0.008$). Within this group, 85.71 % of patients had SS LCH and 14.29 % had MS-RO⁻ LCH. No initial lesions of the disease were recorded in the mouths of MS-RO⁺ LCH patients ($p = 0.008$). Table 5 shows that in 10.52 % of total patients ($n=10$), oral lesion was the only manifestation of LCH, with bone tissue involvement in 90 %, bone-mucosal in 10 %, and mucosal alone in none ($p = 0.011$).

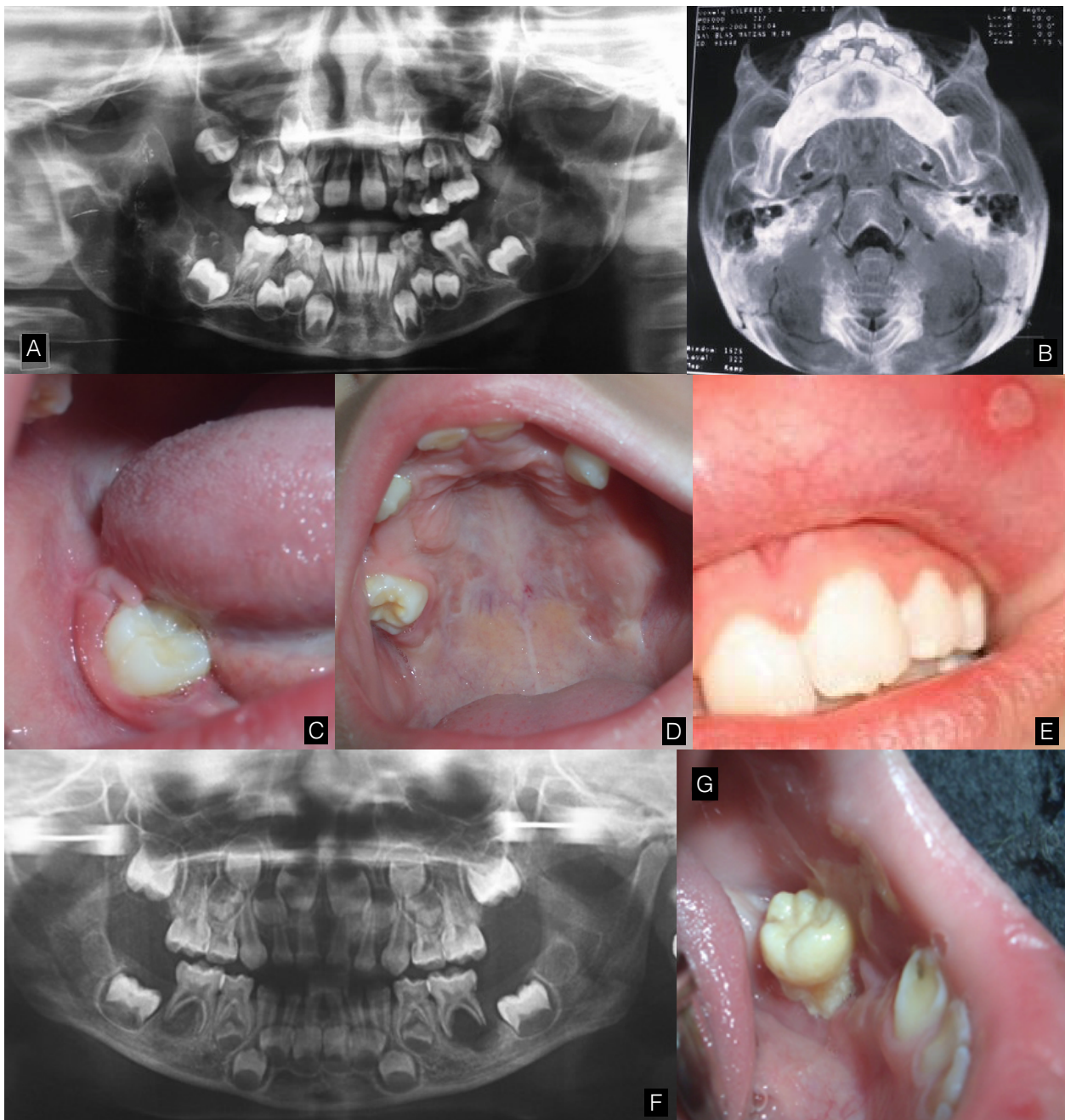


Fig. 1: HCL oral lesions. A) Bone lesions. Panoramic radiograph showing radiolucent areas compatible with osteolytic lesions on both jaws. B) CT scan: osteolysis visible in the mental area. Lesions on mucosa: C) Pericoronitis of tooth 4.6; D) Rash and erosion on palate, and E) Persistent erosive lesion on upper lip mucosa. F) Bone-mucosal lesions. Panoramic radiograph with radiolucent zones compatible with osteolytic lesions of the alveolar bone surrounding teeth 7.5 and 8.5. G) Photograph of tooth 7.5 without bone support, showing exposed root portion.

Table 2. Patients with oral lesions according to LCH subtype

Lesion type	N	%	CI 95	SS LCH	MS RO+ LCH	MS RO- LCH
Bone	21	52.5	36.0-68.5	13	2	6
Bone and mucosal	16	40	24.8-56.7	1	1	14
Mucosal	3	7.5	1.5-20.4	0	0	3
Total	40	42.1	32.0-52.7			

Table 3. Association between ages and tissues involved

Type of oral tissue involved	Average age at time of diagnosis
Bone	2.85 years
Bone-mucosal	1.46 years
Mucosal	2.67 years

Table 4. First lesion in the mouth (n = 14) 14.73% CI 8.2 – 23.5 (n=95)

Type of LCH lesion	N	%	CI 95	SS LCH	MS RO+ LCH	MS RO- LCH
Bone	12	85.8	57.7- 98.3	11	0	1
Bone-mucosal	2	14.2	1.6- 42.8	1	0	1
Mucosal	0	0	0	0	0	0

Table 5. Single LCH lesion in oral cavity, without systemic involvement (n=10), 10.52 %, CI 5.1 – 18.5

Tissue involved	N	%	CI
Bone	9	90	55.4 –99.8
Bone-mucosal	1	10	0.12 –44.5
Mucosal	0	0	0

DISCUSSION

LCH has a broad range of systemic manifestations according to the tissue or organ involved. The current study surveyed and grouped oral lesions in pediatric LCH patients. The results agree with other studies that report that oral lesions may be the first manifestations of LCH, and that the oral cavity is often the only site involved¹⁶⁻²². Oral lesions may also be reactivations of the disease. Sigala et al. (1972)²³ studied 50 cases of LCH in which 36 % of the patients presented oral lesions, and 16 % corresponded to the first manifestation of LCH.

In the current study, 40 out of the total 95 patients (42.1 %) presented LCH lesions in the oral cavity. In 10.52 %, they were the only lesions, while in others, they were part of a broader systemic process. Most lesions involved the lower jaw, in agreement with Pippa Vallejo (2016)¹⁰ regarding lytic bone lesions present in the ascending branch and posterior portion of the mandibular body, which may be single or multiple.

According to Nakamura²⁴, the loss of alveolar bone produces gingival retraction, destruction of keratinized gum, periodontal pockets, swelling and pain, and facilitates early ectopic eruption of permanent molars. In children younger than one year of age, primary teeth erupt prematurely and there is possible loss of permanent tooth buds²¹. In the current study, in patients whose first histiocytosis lesion was in the oral cavity, it involved bone tissue in 85.8%, and bone-mucosa in 14.2%, while mucosa alone was not involved as first LCH lesion.

Rios²⁵ and Erdem²⁰ report that the radiographic image looks like a periodontal cyst, apical granuloma, localized form of periodontitis, or even a neoplastic process, so it is essential to conduct a pathohistological study. When osteolysis involves the alveolar process, the loss of supporting bone tissue leaves the tooth “floating” within the lesion produced by LCH. In some cases, the gum accompanied the bone resorption with loss of insertion level and consequent exposure of the root¹⁰. Lytic lesions observed radiographically in the alveolar bone had a flat base and rounded walls, as if shaped by a hole puncher²⁶. Milán reports that LCH lesions in oral mucosa are ovoid, erythematous, painful upon palpation, and located mainly at the bottom of the vestibular sulcus and jugal mucosa²⁷. LCH oral lesions are not considered high-risk; nevertheless, when they occur on the alveolar processes of the maxilla, they may invade the orbit, malar, or maxillary sinus, and access the base of the skull, with possible risk to the central nervous system¹⁴. Patients with lesions in the upper jaw therefore have different prognosis and treatment¹³. In the current study, oral lesions in the single-system subtype involved bone exclusively, while in the multisystem subtypes, they were varied, involving bone, or mucosa, or both.

When the only evidence of LCH was in the oral zone (edema, teeth with mobility, or pain unrelated to changing teeth), the disease was diagnosed by a pediatric dentist.

At the time of birth, the jaws hold 20 primary teeth

soon to erupt, and 28 permanent teeth in formation. Any alteration in the jawbones may produce sequels in both dentition sets. Age of diagnosis differs according to the different presentation types of the disease. In the current study, children aged 0 to 2 years presented bone-mucosal lesions and corresponded to the multisystem type (MS-RO⁺ LCH and MS-RO⁻ LCH), while in children older than 2 years, the most frequent lesions were bone or mucosal. Preliasco et al.²⁸ agree that younger children would be at higher risk when the oral cavity is involved.

CONCLUSIONS

The oral lesions observed in 40 children differed in extension, and in clinical and radiographic appearance. The aim of this study was therefore to group them based on the type of tissue involved in the lesion. The tissues affected were bone, oral mucosa, or both. A high frequency of oral lesions was observed, which may be one of the first manifestations of the disease, with bone lesions being the most frequent.

CONFLICT OF INTEREST

The authors declare no potential conflicts of interest regarding the research, authorship and/or publication of this article.

ACKNOWLEDGMENTS

The authors thank Dr. Lucia Babino for performing the statistics.

REFERENCES

- Hutter C, Minkov, M. Insights into the pathogenesis of Langerhans cell histiocytosis: the development of targeted therapies. *Immunotargets Ther.* 2016; 5: 81–91. <https://doi.org/10.2147/ITT.S91058>
- Murakami I, M, Iwasaki T, Kuwamoto S, Morimoto A et al. Interleukin-1 loop model for pathogenesis of Langerhans cell histiocytosis. *Cell Commun Signal.* 2015 Feb 22; 13:13. <https://doi.org/10.1186/s12964-015-0092-z>
- Rabassa-Blanco J, Brunet-Llobet L, Marcote-Sinclair P, Balsells-Mejía S et al. Prevalence of, and risk factors for, dental sequelae in adolescents who underwent cancer therapy during childhood. *Oral Dis.* 2022 Jul; 16. <https://doi.org/10.1111/odi.14317>
- DiCaprio MR, Roberts TT. Diagnosis and management of Langerhans cell histiocytosis. *J Am Acad Orthop Surg.* 2014 Oct;22(10):643-52. <https://doi.org/10.5435/JAOS-22-10-643>
- Casanovas, A.; Elena, G.; Rosso, Diego; Histiocitosis de células de Langerhans; Sociedad Argentina de Hematología; Revista Argentina de Hematología 18; 1; 2014; 60-66 oai:ri.conicet.gov.ar:11336/16172
- Bechan GI, Egeler RM, Arceci RJ. Biology of Langerhans cells and Langerhans cell histiocytosis. *Int Rev Cytol.* 2006; 254:1-43. [https://doi.org/10.1016/S0074-7696\(06\)54001-X](https://doi.org/10.1016/S0074-7696(06)54001-X)
- Kumar N, Sayed S, Vinayak S. Diagnosis of Langerhans cell histiocytosis on fine needle aspiration cytology: a case report and review of the cytology literature. *Patholog Res Int.* 2011; 2011:439518. <https://doi.org/10.4061/2011/439518>
- Minkov M, Grois N, Braier J, Rosso D, Arico M, Broadbent V, Gadner H, Ladisch S, et al. Immunosuppressive treatment for chemotherapy-resistant multisystem Langerhans cell histiocytosis *Med Pediatr Oncol.* 2003;40(4):253-6. <https://doi.org/10.1002/mpo.10167>
- Morimoto A, Ishida Y, Suzuki N, Ohga S, Shioda Y, Okimoto Y, Kudo K, Ishii E; HLH/LCH Committee of the Japanese Society of Pediatric Hematology. Nationwide survey of single-system single site Langerhans cell histiocytosis in Japan. *Pediatr Blood Cancer.* 2010;54(1):98-102. <https://doi.org/10.1002/pbc.22224>
- Pipa Vallejo A, Pipa Muñoz M, Pipa Muñoz C, Gangoi-ti Moratino Z et al. Histiocitosis de células de Langerhans con implicación oral: a propósito de un caso. *Av.*

Patients with bone-mucosal lesions, with multisystem LCH with or without risk organ involvement were the youngest at the time of diagnosis. No evidence was found of LCH subtype influencing the likelihood of developing oral manifestations.

Lesions on the maxilla may spread to the central nervous system. Thus, pediatric patients with oral involvement, and according to their systemic situation, may have different prognosis and need to receive different courses of treatment.

These results show that interdisciplinary work from the beginning of the disease may improve LCH patient wellbeing. Pediatricians and pediatric dentists should check the oral cavity thoroughly to identify any clinical or radiographic manifestations of LCH. If the pediatric dentist is the first to see a child with LCH lesion confirmed by biopsy, they must immediately confer with an oncologist in order to locate any other systemic lesions that might be present. It is recommendable to take panoramic radiographs periodically to monitor evolution or diagnose any new lesions.

FUNDING

This study was supported by a Grant from Facultad de Odontología, Universidad de Buenos Aires–FOUBA Res. (CD) N°330/19-01.

- Odontostomatol 2016; 32(4):187-193., ISSN 02131285 http://scielo.isciii.es/scielo.php?script=sci_arttext&pid=S0213-12852016000400002&lng=es.
11. Spodzieja K, Olczak-Kowalczyk D. Premature Loss of Deciduous Teeth as a Symptom of Systemic Disease: A Narrative Literature Review. *International Journal of Environmental Research and Public Health* 2022; 19(6):3386. <https://doi.org/10.3390/ijerph19063386>
 12. Cisternino A, Farah Fusco N, Ferrero S, Rasperini G. Role of multidisciplinary approach in a case of Langerhans cell histiocytosis with initial periodontal manifestations *Int J ClinExpPathol* 2015;8(10):13539-13545. PMID: PMC4680515
 13. Emile J F, et al., Revised classification of histiocytoses and neoplasms of the macrophage-dendritic cell lineages, *Blood* 2016;127(22):2672-81. <https://doi.org/10.1182/blood-2016-01-690636>
 14. Braier J, Pollono D, Rey G, Latella A, De Socio S, Tomarchio S, Rosso D, Goldberg J. Reactivations in Langerhans cell histiocytosis (LCH). *Histiocyte society 18 th Annual Meeting Porto, Portugal. Med Pediatr Oncol* 2003;(40):3;180
 15. Felstead AM, Main BG, Thomas SJ, Hughes CW. Recurrent Langerhans cell histiocytosis of the mandible. *Br J Oral Maxillo fac Surg.* 2013;51(3):264-265. <https://doi.org/10.1016/j.bjoms.2012.10.005>
 16. Shirley J, Thornton J. Oral manifestations of Langerhans' cell histiocytosis: Review and report of case. *ASDC J Dent Child* 2000; July-August:293-6. PMID: 10997248.
 17. Hernández Juyol M, Boj Quesada J R, Gallego Melcon S. Manifestaciones orales de la Histiocitosis de células de Langerhans a propósito del caso de un niño de dos años. *Med Oral* 2003;8:19-25. *Medicina Oral S. L. C.I.F. B 96689336-ISSN 1137-2834*
 18. Hicks J, Flaitz CM. Langerhans cell histiocytosis: Current insights in a molecular age with emphasis on clinical oral and maxillofacial pathology practice. *Oral Surgery, Oral Med Oral Pathol Oral RadiolEndodontology.* 2005;100 (2 SUPPL.):42-66 <https://doi.org/10.1016/j.tripleo.2005.06.016>
 19. Madrigal-Martínez-Pereda C, Guerrero-Rodríguez V, Guisado-Moya B, Meniz-García C, Langerhans cell histiocytosis: Literature review and descriptive analysis of oral manifestations. *Med Oral Patol Oral Cir Bucal.* 2009;1;14 (5):E 222-8. PMID: 19218906
 20. Erdem AP, Kasimoglu Y, Sepet E, Gencay K, Sahin S, Dervisoglu S. Oral manifestations may be the first sign of Langerhans cell histiocytosis. *Oral Health Prev Dent.* 2013;11(1):57-59. <http://www.ncbi.nlm.nih.gov/pubmed/23507682>.
 21. Merglová V, Hrusak D, Boudová L, Mukensnabl P, Valentová E, Hosticka L. Langerhans cell histiocytosis in childhood—Review, symptoms in the oral cavity, differential diagnosis and report of two cases. *J Cranio-Maxillofacial Surg.* 2014;42(2):93-100. <https://doi.org/10.1016/j.jcms.2013.03.005>
 22. Fernández de Preliasco V, Benchuya C, Pavan V. Lesiones bucales asociadas con la enfermedad de Histiocitosis de Células de Langerhans en odontopediatría. *Revista de la Asociación de la Academia Nacional de Odontología.* 2011;9(9):12-17.
 23. Sigala JL, Silverman S Jr, Brody HA KJ. Dental involvement in histiocytosis. *Oral Surg Oral Med Oral Pathol.* 1972;33(1):42-48. [https://doi.org/10.1016/0030-4220\(72\)90206-X](https://doi.org/10.1016/0030-4220(72)90206-X)
 24. Nakamura S, Bessho K, Nakao K, Iizuka T, Scott RF. Langerhans' cell histiocytosis confined to the jaw. *J Oral Maxillofac Surg* 2005; 63:989-95. <https://doi.org/10.1016/j.joms.2004.07.029>
 25. Rios C, Gonzalez Diaz M, Bello Rodriguez R, Torrens de la Nuez R. Granulomatosis de células de Langerhans. Presentación de un caso. *Rev. Cubana Estomatológica* 1998;35(3):124-6. ISSN 1561-297X
 26. Benchuya C. Estudio Básico Clínico de Pacientes Pediátricos con Histiocitosis de células de Langerhans. Tesis de Doctorado, 2015. Facultad de Odontología Universidad de Buenos Aires.
 27. Milian MA. Langerhans's cell histiocytosis. *Med Oral Patol Oral Cir Bucal* 2005 Mar-Apr;10(2):185. English, Spanish. PMID: 15735553.
 28. Preliasco V F; Benchuya C; Pavan V; de la Cal C; Ganzinelli S Sterin_Borda L. IL-1β and PGE2 levels are increased in the saliva in children with Langerhans cell histiocytosis. *J Oral Pathol Med* 2008; 37(9): 522-7. <https://doi.org/10.1111/j.1600-0714.2008.00675.x>